

An evaluation of the Film-Based and Digital Panoramic Radiographic Quality

Rand Shaker Al-Ani
BDS, MSc (Assist Lect)

Dept of Oral and Maxillofacial Surgery
College of Dentistry, University of Mosul

ABSTRACT

Aims: To compare the image quality of panoramic radiographs obtained with charge-coupled device (CCD) and screen-film systems. **Materials and methods:** True Panoramic radiographs were taken in 26 patients each with both screen-film and CCD systems. The images were obtained with TRATO 2000, CE by VILLA SISTEMI MEDICALIS-ITALY with regular intensifying screen type Kodak Lanex and 6 x 12 inch screen type film used for film-based projection, while Dimax3 digital system pan/ceph, PLANMECA, Helsinki, Finland with CCD X-ray image sensor (the size of the panoramic sensor was 15 x 30 cm and the resolution of the panoramic image was around 230 dpi, used for digital projection. Both X-ray machines were operated at range of 70-80 kV and 10-12 mA, according to the patient age. Altogether, the digital images files were displayed on 17 inch monitor, brightness and contrast were fixed and no enhancement was made before the digital images files were saved. While the film-based images after processing were viewed on the viewer box. Image quality was assessed by rating the visibility of five anatomical landmarks commonly found on panoramic radiographs: The superior and inferior cortex of the mandibular canal, the superior and inferior margin of the mental foramen, the lower and anterior border of the maxillary sinus, the lower border of the mandible, and the articular eminence. For each image, the given landmark was rated as good (image of excellent diagnostic quality), acceptable (image of diagnostic quality but should be improved), or unacceptable (image not of diagnostic quality). Each image was then given an overall evaluation rating of good, acceptable, or unacceptable. **Results:** The data collected from the evaluation of the digital and film-based images by the three examiners, were analyzed by t-test. The image quality, as represented by each of the five anatomical landmarks, and the overall rating for each system were expressed as the mean scores of the three examiners. The difference between the film-based and the digital images systems was not statistically significant ($P>0.05$). **Conclusions:** It was concluded that digital panoramic radiographs are equivalent to film-based images for the five anatomical landmarks.

Key Words: Digital, film-based, panoramic.

Al-Ani RSh. An evaluation of the Film-Based and Digital Panoramic Radiographic Quality. *Al-Rafidain Dent J.* 2008; 8(1): 67-71 .

*Received:*13/3/2008

*Sent to Referees:*14/3 /2008

Accepted for Publication: 15/5/200

INTRODUCTION

In the daily practice of dentistry, panoramic radiography takes second place in importance to intraoral radiography. However, panoramic imaging may be more beneficial to patients because it offers both excellent evaluations of jaw fractures, tooth development, and maxillary sinus disorders. It also has the additional benefits of reduced radiation exposure compared with full-mouth intraoral radiographs^(1,2), and the availability of modifications to standard intraoral techniques for pediatric and handicapped patients as well as those with gag reflex sensitivity⁽³⁾.

In the last decade, many types of

digital radiographic systems, including those for panoramic radiography, have available that are based on either storage phosphate plate technology or charge-coupled devices (CCDs). In either case, the method is similar to conventional panoramic radiography, but the receptor, processing, display, and storage differ from film-based imaging⁽⁴⁾.

In contrast to film-based panoramic radiographs, digital panoramic radiography allows the correction of errors in density and contrast because the digital image can be post-processed. Furthermore, due to their wider dynamic range, most

digital receptors are less sensitive to variations in exposure⁽⁵⁾. The solid-state linear x-ray image sensor is composed of a linear array of silicon photodiodes covered by a scintillator, which detects x-ray passing through the object being examined⁽⁶⁾.

The image layer is a three dimensional curved zone (or focal trough) in which the structures lying within the layer are reasonably well defined on final panoramic image. While objects outside the image layer are blurred, the vertical and horizontal unequal magnified, or reduced in size and are sometimes disordered to the extent of not being recognizable. Only the points in the thin central plane of the image layer are projected sharply, while points at any distance from the plane become blurred, even in the image layer. Teeth and the alveolar processes have finite thickness and are, therefore, subject to these problems⁽⁷⁾.

MATERIALS AND METHODS

A twenty six patient have been selected randomly in this research, each patient subjected for film-based and digital panoramic radiographic examination, Figure 1: (A), (B). Panoramic x-ray machine type STRATO 2000, CE by VILLA SISTEMI MEDICALIS-ITALY with regular intensifying screen type Kodak Lanex and 6 x 12 inch screen type film, used for film-based projection; while Dimax3 digital system pan/ceph, PLANMECA, Helsinki, Finland with CCD x-ray image sensor used for digital projection the size of

the panoramic sensor was 15 x 30 cm and the resolution of the panoramic image was around 230 dpi.

Both x-ray machines were operated at range of 70–80 kVp and 10–12 mA according to the patient age. Altogether, the digital image files were displayed on 17 inch monitor, brightness and contrast were fixed and no enhancement was made before the digital image files were saved. While the film-based images after processing were viewed on the viewer.

Three independent examiners (radiographic specialists), rated the film-based and digital radiographic images on a three point scale: (1= unacceptable, 2= acceptable, 3= good). Image quality was assessed by rating the visibility of five anatomical landmarks commonly found on panoramic radiographs, Figure (2):

- The superior and inferior cortex of the mandibular canal.
- The superior and inferior margin of the mental foramen.
- The lower and anterior border of the maxillary sinus.
- The lower border of the mandible.
- Articular eminence.

For each image, the given landmark was rated as good (image of excellent diagnostic quality), acceptable (image of diagnostic quality but should be improved), or unacceptable (image not of diagnostic quality). Each image was then given an overall evaluation rating of good, acceptable, or unacceptable.

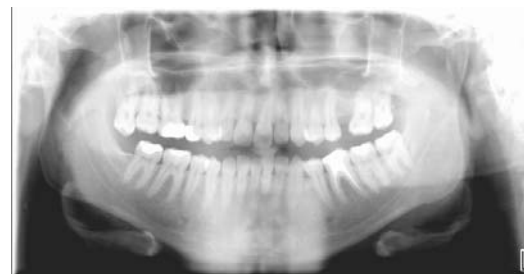
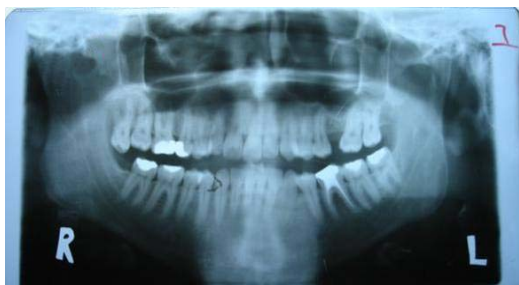
Figure 1 : (A) film-based panoramic radiograph, (B): digital panoramic radiograph.

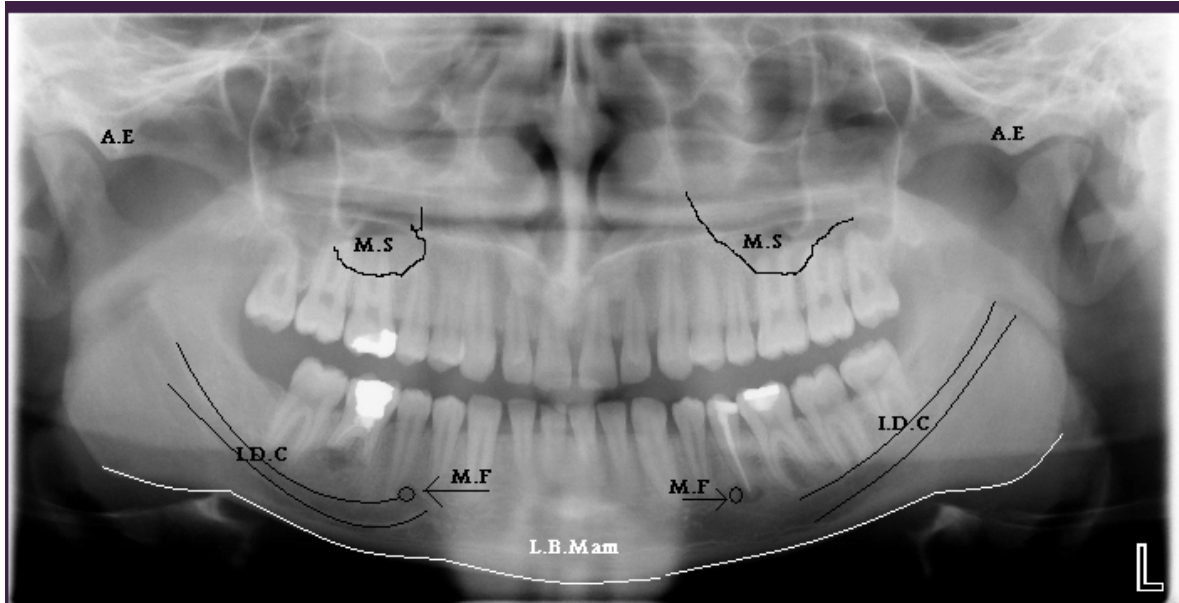


Figure 2: Digital panoramic radiograph shows the five anatomical landmarks: **A.E**: Articular eminence. **M.S**: lower and anterior border of the maxillary sinus. **I.D.C**: superior and inferior cortex of the mandibular canal. **M.F**: superior and inferior margin of the mental foramen. **L.B. Man**: lower border of the mandible

RESULTS

The data collected from the evaluation of the digital and film-based images by the three examiners, were analyzed by t-test. The image quality, as represented by each of the five anatomical landmarks, and the overall rating for each system were expressed

as the mean scores of the three examiners as shown in the Table (1).

The Table (1) showed that there was no significant difference ($P>0.05$) in image quality between the two techniques of the five anatomical landmarks. The film-based technique was rated slightly more than the digital technique in all regions except in the inferior dental canal.

Table (1): Compare the image quality between the two techniques of the five anatomical landmarks.

Variables	Number	Technique	Mean	Mean differences	STD.	t- value	P>0.05
I.D.C	26	Film-based.	1.3323	0.077	0.377956	0.506547	N.S
		Digital.	1.41		0.455807		
M.F.	26	Film-based.	1.8588	0.4235	0.526789	0.00384	N.S
		Digital.	1.4353		0.479093		
M.S.	26	Film-based.	1.2942	0.0508	0.424803	0.634221	N.S
		Digital.	1.2434		0.334604		
L.B.Man.	26	Film-based.	1.1023	0.0385	0.206035	0.45956	N.S
		Digital.	1.0638		0.16366		
A.E.	26	Film-based.	1.5757	0.1527	0.528932	0.275172	N.S
		Digital.	1.4230		0.467125		

N.S: not significant; I.D.C: superior and inferior cortex of the mandibular canal; M.F: superior and inferior margin of the mental foramen; M.S.: lower and anterior border of the maxillary sinus; L.B.Man.: lower border of the mandible; A.E: Articular eminence.

DISCUSSION

In this study, image quality was used to compare between two different systems, where the examiners are radiographic specialists. The images were examined at the same software program, to provide identical facilities for image enhancement, and to exclude different quality scores, if they had been evaluated with the examiners own software.

Image quality in the two panoramic radiographs was scored acceptable, and show: No significant differences between them; while the film-based radiographs rated slightly more than the digital radiographs. This may be related to many reasons according to the differences between the film-based and digital radiography which includes range of radiation exposure, dose and sensitivity to radiation, signal-to-noise ratio and resolution. All PSP (Photo-Stimulable Phosphorus Plate) and CCD detectors systems achieve image resolution in the range of 6 to 12 line pairs per millimeter. This range of resolution was similar to that in extraoral images acquired with screen-film combinations ⁽⁷⁾.

In addition to the spatial resolution is important in viewing the fine detail on the radiographic image. This characteristic allows the sensor to recognize two objects placed close together as separated image, which is a feature that is very important in diagnosis ⁽⁸⁾.

Farman and Farman ⁽⁹⁾ stated that both film-based and digital formats produce comparable images with spatial resolution of 4 l p/mm. In contrast to PSP systems, the dynamic range of CCDs was less than that of radiographic film. Practically this means that the range of exposures over which CCD systems responded with images in the diagnostically useful density range was less than that of both PSP systems and radiographic film. The increased latitude achieved by PSP systems also allowed for image acquisition with less radiation exposure than with CCD systems ⁽⁷⁾.

White *et al.* ⁽¹⁰⁾ reported that digital sensors with wide dynamic range are more desirable in clinical dentistry because they produce an image over a wide exposure

range. It thus allows for small differences in density and produces more accurately imaged objects. They reported that CCD sensors showed a range of 100-to-1 of high versus low detectable radiation exposure, whereas film's dynamic range was about 1000-to-1. CCD and Photo stimulable sensors have a linear response to the radiation. That meant the image density was directly proportional to the amount of radiation dosage. Linear response as well as high sensitivity to x-ray response was very important characteristics of a sensor.

Another characteristic of the digitization system is the noise level; which is a result of a conversion from analog to digital image. The recording medium such as film or sensor, or electronic components of the imaging system, adds additional noise (or an image distracter) that contributes to degradation of the image and eventually poor diagnostic quality ⁽¹⁰⁾.

Research indicated that the lower the signal to-noise ratio, the more sensitivity of the sensor to radiation. CCD sensors were reported to have lower electronic noise (or increased signal-to-noise ratio) than films, thus providing an observer with better diagnostic information ⁽⁸⁾.

Ramamurthy *et al.* ⁽¹¹⁾ stated that there were several problems associated with CCD and SPP-based systems. For examples, no scintillator is 100% efficient: there are always a proportion of x-ray photons that flows through the scintillator without being converted to visible photons. Not only the lost or unconverted x-ray photons do not contribute to the image, they also impact the CCD at high energy, creating noise in the image and, in the long run, damaging the imager.

The results of present study were supported by White *et al.* ⁽¹²⁾ when they stated that the quality of digital image was diagnostically equivalent to that of a traditional dental film. Other significant benefits associated with this technology are quick image acquisition, elimination of harmful processing solutions, image manipulation, and decreased radiation to the patient.

Other studies ^(9, 13) were agreed with this study, they found that there was no significant difference in image

quality between film-based and digital radiography.

CONCLUSIONS

It was concluded that digital panoramic radiographs are equivalent to film-based images for the five anatomical landmarks.

REFERENCES

1. McDavid W, Dove S, Welander U, Tronje G. Electronic system for digital acquisition of rotational panoramic radiographs. *Oral Surg Oral Med Oral Pathol.* 1991; 71: 499–502.
2. Dove S, McDavid W, Welander U, Tronje G. Preliminary evaluation of a digital system for rotational panoramic radiography. *Oral Surg Oral Med Oral Pathol.* 1992; 37: 623–32.
3. Hassfeld S, Zoller J, Wiedenmann R, Muhling J. The new Siemens Orthophos Digital, a direct digital panoramic radiography system. In: Lemke HU, Inamura K, Jaffe CC, Vannier MW, Editor. *Computer assisted radiology (CAR)95.* Berlin: Springer; 1995: 1002–73.
4. Bun-Ka Yiu, Simon Chi-Man Ip, Simon Chi-Yung Liu, Philip Chi-Hong Ng, Gerald Hin-Ho Siu. Digital dental panoramic radiography: evaluation of image quality in four imaging systems. *Hong Kong Dental Journal.* 2005; 2: 19–23.
5. Dove BS, McDavid WD. Digital panoramic and extraoral imaging. *Dent Clin North Am.* 1993; 37 (4): 541–551.
6. Kaeppler G, Axmann-Kremar D, Reuter I, Meyle J, Gomez-Roman G. A clinical evaluation of some factors affecting image quality in panoramic radiography. *Dentomaxillofac Radiol.* 2000; 29: 81–4.
7. Pharoah MJ, White SC. *Oral Radiology Principles and Interpretation.* 4th Edition. St. Louis, Mosby, 2000. Pp: 225–226.
8. Digital Imaging in Dentistry. Retrieved March 10, 2002 from [www:http://ddsdx.uthscsa.edu/dig/digtutor.htm](http://ddsdx.uthscsa.edu/dig/digtutor.htm) I.
9. Farman AG, Farman TT. Extraoral and Panoramic Systems. In: Miles D, editor. *Applications of Dental Imaging Modalities in Dentistry.* *Dent Clin North Am.* 2000 Apr; 44(2): 257–72 (Review).
10. White, SC, Yoon D, Tetradis S. Digital Radiography in Dentistry. What It Should Do for You. *J Cal. Dent. Ass.* 1999. Retrieved March 10, 2002 from [www:-http://www.cda.org/member/pub/journal/jour1299/digital.htm](http://www.cda.org/member/pub/journal/jour1299/digital.htm) I.
11. Ramamurthy R, Canning C, Scheetz J, Farman A. Implant of ambient lighting intensity and duration on the signal-to-noise ratio of images from photo-stimulable phosphor plates processed using DenOptix and ScanX systems. *Dentomaxillofac Radiol.* 2004; 33: 307–11.
12. White SC, Yoon D, Tetradis S. Digital Imaging: A Vision for future. Retrieved March 12, 2002 from [www: http://www.dent.ucla.edu/sod/depts/oral_rad/Vision-Statement.htm](http://www.dent.ucla.edu/sod/depts/oral_rad/Vision-Statement.htm) I.
13. Molander B, Grondahl H, Ekestubbe A. Quality of film-based and digital panoramic radiography. *Dentomaxillofac Radiol.* 2004; 33: 32–6.